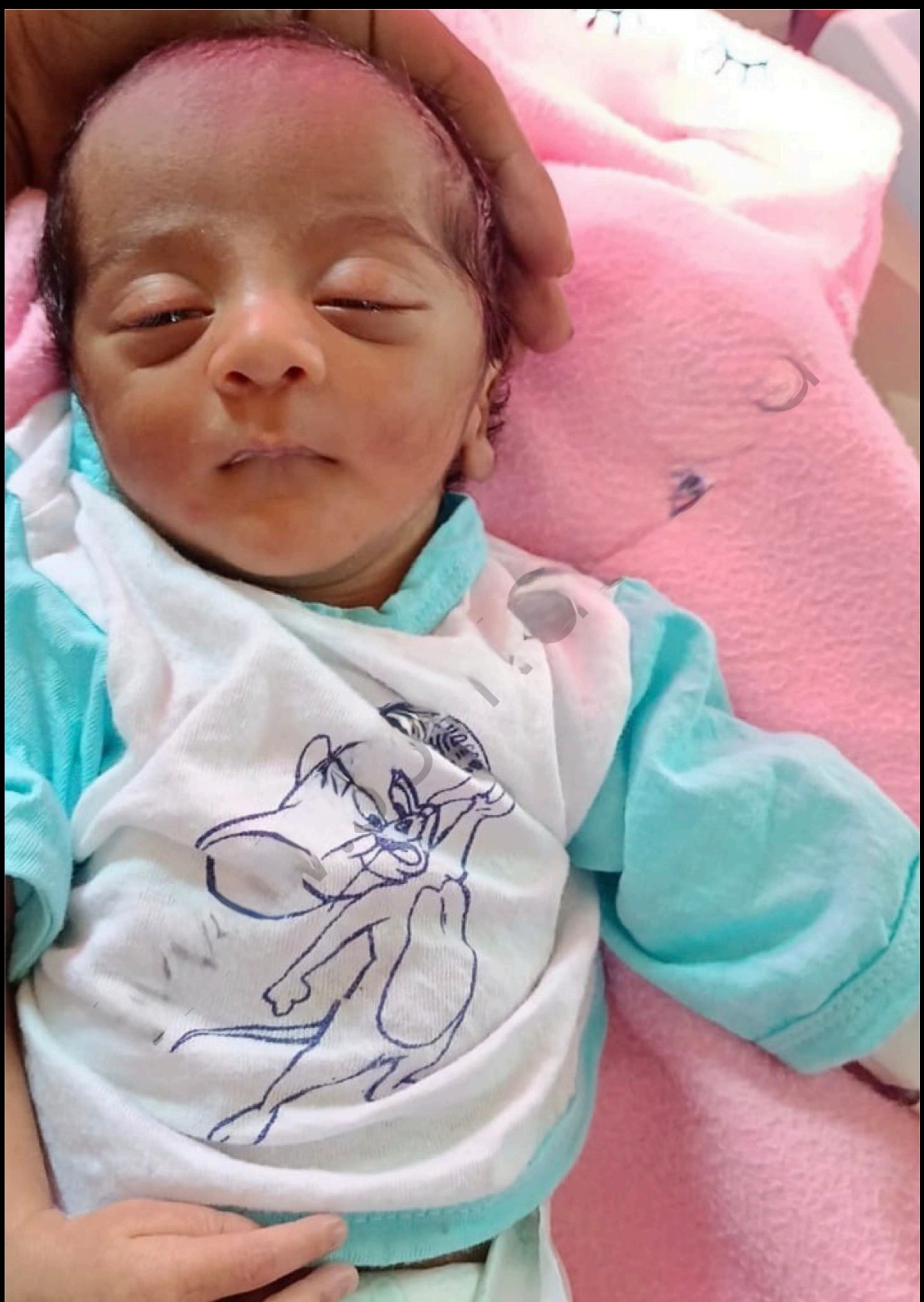





उत्तर प्रदेश सरकार  
**GOVERNMENT OF UTTAR PRADESH**  
 चिकित्सा एवं स्वास्थ्य विभाग  
**DEPARTMENT OF MEDICAL AND HEALTH**  
 ग्राम पंचायत भण्डसरिया  
**GRAMA PANCHAYAT BHANDSARIA**

जन्म प्रमाण-पत्र  
**BIRTH CERTIFICATE**

(जन्म और मृत्यु रजिस्ट्रीकरण अधिनियम, 1969 की धारा 12/17 तथा उत्तर प्रदेश जन्म और मृत्यु रजिस्ट्रीकरण नियम 2002 के नियम 5(1)(1)(1)(1) के तहत जारी किया गया)  
 (ISSUED UNDER SECTION 12/17 OF THE REGISTRATION OF BIRTHS AND DEATHS ACT, 1969 AND UP REGISTRATION OF BIRTHS & DEATHS RULES 2002)


यह प्रमाणित किया जाता है कि निम्नलिखित सूचना जन्म के मूल लेख से ली गई है जो कि ग्राम पंचायत भण्डसरिया तहसील/ब्लॉक/जिला/संघ प्रदेश उत्तर प्रदेश, भारत के रजिस्टर में उल्लिखित है।

THIS IS TO CERTIFY THAT THE FOLLOWING INFORMATION HAS BEEN TAKEN FROM THE REGISTER FOR GRAMA PANCHAYAT BHANDSARIA OF TAHSIL/BLOCK/DISTRICT KHERI OF STATE/UNION TERRITORY OF UTTAR PRADESH, INDIA

नाम / NAME: VHAAN	लिंग / SEX: MALE
आधार संख्या / AADHAAR NUMBER:	
जन्म तिथि / DATE OF BIRTH: 06-02-2026 SIXTH FEBRUARY TWO THOUSAND TWENTY SIX	जन्म स्थान / PLACE OF BIRTH: KHERI, KHERI, UTTAR PRADESH, 262701
माता का नाम / NAME OF MOTHER: PRIYANKA VERMA	पिता का नाम / NAME OF FATHER: RANJAN VERMA
माता का आधार संख्या / AADHAAR NUMBER OF MOTHER: XXXX-XXXX-5443	पिता का आधार संख्या / AADHAAR NUMBER OF FATHER: XXXX-XXXX-3409
बच्चे के जन्म के समय माता-पिता का पता / ADDRESS AT THE TIME OF BIRTH OF THE CHILD: BEHTA, AIRA ESTATE, AIRA, DHAURAHARA, KHERI, UTTAR PRADESH, 262722	माता-पिता का स्थायी पता / PERMANENT ADDRESS OF PARENTS: BEHTA, AIRA ESTATE, AIRA, DHAURAHARA, KHERI, UTTAR PRADESH, 262722

पंजीकरण संख्या / REGISTRATION NUMBER: K252509143810000214  
 पंजीकरण तिथि / DATE OF REGISTRATION: 18-02-2026

जारी करने की तिथि / DATE OF ISSUANCE:  
18-02-2026



अधिकारी के हस्ताक्षर / SIGNATURE OF ISSUING AUTHORITY:  
 चिकित्सा एवं स्वास्थ्य विभाग  
 DEPARTMENT OF MEDICAL AND HEALTH  
 ग्राम पंचायत भण्डसरिया  
 KHERI, UTTAR PRADESH

"This QR code can be used to check the authenticity of the certificate"

जन्म और मृत्यु का रजिस्ट्रेशन सुनिश्चित करें / ENSURE REGISTRATION OF EVERY BIRTH AND DEATH

SGRH/DM/MC/Cost -Ttmt/E-218

# Sir Ganga Ram Hospital : New Delhi

## MEDICAL CERTIFICATE FOR COST OF TREATMENT

Certificate No: DM/MC/FE/ Pediatric Cardiac Sciences 2026

(Department)

(Running No.)

1	Name	: Vihaan (aka B/o Priyanka Verma)
2	Age	: 1 month 11 days
3	Sex	: Male
4	Adhaar No	:
5	Patient Registration No	: 3693917
6	Date patient examined	: 17/03/2026
7	Brief Clinical Summary (Only relevant salient features like Nature of illness Symptoms Probable cause)	: Cyanosis (Cyanosis)
8	Diagnosis 'Cyanotic CHD	: DORV, PM-VSD, mild mitral and aortic regurgitation, Severe PDA, severe segmental LPA stenosis.
9	Treatment Planned	: Duct is currently restrictive. PA to Aorta RTT shunt (w/valve; on pump)
10	Inpatient / Outpatient	: Inpatient
11	Duration of hospitalization if any	: 11/11
12	Cost of Treatment	: ₹ 1,00,000/-
13	Purpose for which medical certificate issued	: Financial Assistance
14	Medical Certificate issued for	: G.M. Fund, UP

Patien Impression

Date: 17/03/2026

(Signature Consultant)

State ID Qualifications & DMC No

**Dr. (Prof.) RAJA JOSHI**  
 MCh (CNS) Fellow (Peds Card Surg. USA)  
 Senior Consultant, Pediatric Cardiac Surgeon  
 Senior, Dept. of Pediatric Cardiac Sciences  
 Sir Ganga Ram Hospital  
 MCI Reg. No 11934 DMC Reg No 26625

Date: 17/3/2026

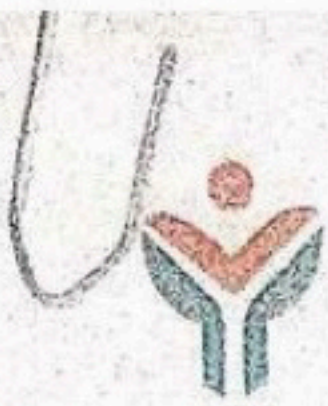Director Medical

**Dr. SUCHITA KATOCH**  
 Medical Superintendent  
 Sir Ganga Ram Hospital  
 Rajinder Nagar, New Delhi-110050

**Dr. ADY ANESTH**  
 Dr. ENDR KUMAR PANDEY  
 ADVOCATE  
 NOTARY

Date: 17/5/2026

Validity upto: 17/5/2026



SIR GANGA RAM HOSPITAL  
Trust of Generations

# Dr. (Prof) Raja Joshi

MBBS, MS, MCh, (CTVS)  
Fellowship (Cleveland Clinic, USA)

Senior Consultant Neonatal & Pediatric Cardiac Surgeon  
Chairman, Department of Pediatric Cardiac Sciences  
Sir Ganga Ram Hospital, New Delhi  
MCI Reg. No. 11934, DMC Reg. No. 26626



Vihaan (aka B/O Priyanka Verma)

0y 1m 11d / Male

REG NO: 3693917

PCS ID: --

DOB: Feb. 6, 2026

WEIGHT: 3.10 kg

HEIGHT: 51.00 cm

HEART RATE (BPM): 137

SPO2: 76 %

REF. DOCTOR: Dr. G.K. Singh

DATE: March 17, 2026, 2:07 p.m.

**PERSONAL HISTORY:**

Term, AGA (B wt= 2.5Kg)

**PRESENT COMPLAINTS:**

Saturations have dropped to 76%

**DIAGNOSIS:**

SS, LC, B/L SVC, DORV, Commitable PM-VSD + additional mid-muscle and Long segment LPA stenosis

**CLINICAL FINDINGS:**

This time has gained weight approximately 800-900 gms over previous visit

**ECHOCARDIOGRAM:**

Same findings as before with further increase in size of LVOT tunnel. Concern for the future LVOT tunnel

**MEDICATIONS:**

TAB INDERAL / CIPLAR 10MG (1/8TH) BID  
CONTINUE IRON DROPS

**REMARKS/ADVICE:**

Procure CMRF letter from [unclear]

**NEXT FOLLOW-UP:**

R/A 2 weeks for [unclear] (BUN and Creatinine) under c/o Dr Anil Kumar-PCS

(TO CONTACT US AS ADVISED WITH APPOINTMENT OR REPORT ANY ABNORMAL SYMPTOMS)

*[Handwritten signature]*

25: 1ml FF ↑ volume  
6° Simyl MCT OIL per feed  
gradually ↑ by 2° every  
3days till 15° per feed

**S.G.R.H** - Rajinder Nagar, New Delhi - 60, Ph. : 011-42251700,  
42251800, 42254000, Fax No. : 91-11-25861002, EPBX : 011-25750000  
OPD Room No. F-57, Timings : 9.00 am - 5.00 pm Monday to Saturday  
For Appointment Call : +91 9873818788, OPD ☎ 011-42251757,  
Mobile : +91 9811118187, e-mail : [dr.raja\\_joshi@yahoo.com](mailto:dr.raja_joshi@yahoo.com)





## Department of Pediatric Cardiac Sciences Echocardiography Report

B/O Priyanka Verma  
DOB: Feb. 6, 2026  
REF. DOCTOR: Dr. G.K. Singh

0y 1m 11d / Male  
WEIGHT: 3.10 kg

REG NO: 3693917  
HEIGHT: 51.00 cm

PCS ID: --  
BSA: 0.201

DATE OF ECHO: March 17, 2026

PATIENT LOCATION: OPD

ECHO TYPE: Trans Thoracic Echocardiogram

### Cardiac Position

Abdominal Situs Solitus.  
Levocardia.

### Cardiac Segments

Atrial Situs Solitus.  
D-loop ventricle.  
AV concordance.

Two patent AV Valves.

### Double Outlet Right ventricle

Normally related great arteries.

### Veins

Systemic Venous drainage - Bilateral  
Normal Pulmonary Venous drainage

### Atria

Interatrial septum- (Right shunt)

Dilated RA

LA size- Long Axis

### Atrioventricular Valves

Normal

Normal

### Valves

Normal Left ventricle.

Dilated Right ventricle- Significant Right ventricular Hypertrophy,

RV Free wall 4.5mm

Interventricular septum- Large Malaligned VSD with Outlet extension ( 8mm ), Ratable Aorta

Additional Mid muscular VSD( Bidirectional shunt ) ( 2.5mm )



### Ventricles

Normal Left ventricle.

**Dilated Right ventricle- Significant Right ventricular Hypertrophy,  
RV Free wall 4.5mm**

Interventricular septum- **Large Malaligned VSD with Outlet extension ( 8mm ), Routable Aorta  
Additional Mid muscular VSD( Bidirectional shunt ) ( 2.5mm )**

IVSd (mm)	IVSd z-score
9.0	+8.31
PWd (mm)	PWd z-score
4.0	+0.91

### Conotruncus

LVOT and aortic valve- **Systolic Doming of Aortic valve, Functional Aortic valve  
70 - 90% Aortic Override, Sub Aortic VSD on Routing size 8mm**  
RVOT and pulmonary valve - **RVOT Peak gradient 100mmHg (Infundibular + valvular) Severe PS ( Small Antegrade flow )**

Aortic Valve annulus (mm)	Aortic Valve annulus z-score
12	+6.49
Pulmonary Valve annulus (mm)	Pulmonary Valve annulus z-score
4.5	-5.33

### Great Arteries

Normal ascending aorta, arch and descending aorta.  
Confluent branch pulmonary artery 6mm  
**LPA proximal 1.3mm stenosis, LPA proximal stenosis, LPA distal 4.0mm**  
**Long Tortuous Vessel Arch ( 1-2mm ), Left to Right shunt**  
Peak gradient 20mmHg  
No Coarctation

Ascending Aorta (mm)	Ascending Aorta z-score
12	+3.85

Normal LV function.  
Normal LV function.

### Effusion

No pericardial effusion.



**INTERPRETATION**

- DOUBLE OUTLET RIGHT VENTRICLE
- LARGE MALALIGNED VSD ( Rountable Aorta )  
ADDITIONAL MID MUSCULAR VSD
- PROXIMAL LONG SEGMENT LPA STENOSIS
- SIGNIFICANT RIGHT VENTRICULAR HYPERTROPHY
- BILATERAL SVC
- DILATED RA/ RV
- GOOD BIVENTRICULAR FUNCTION



**Dr. Neeraj Aggarwal**

MD ( Pediatrics), Fellow Ped Cardiology  
Sr Consultant, Pediatric Cardiologist  
SIR GANGA RAM HOSPITAL

**Dr. Mridul Agarwal**

MD ( Pediatrics), FNB Ped Cardiology  
Sr Consultant, Pediatric & Fetal CV  
SIR GANGA RAM HOSPITAL

**Dr. Anshu Aggarwal**

DrNB Ped Cardiology  
Sr Consultant, Pediatric Cardiologist  
SIR GANGA RAM HOSPITAL

Report typed by: Pooja Kumari

**Dr. Anshu Aggarwal**



SIR GANGA RAM HOSPITAL  
Trust of Generations

# Dr. (Prof) Raja Joshi

MBBS, MS, MCh, (CTVS)  
Fellowship (Cleveland Clinic, USA)

Senior Consultant Neonatal & Pediatric Cardiac Surgeon  
Chairman, Department of Pediatric Cardiac Sciences

Sir Ganga Ram Hospital, New Delhi

MCI Reg. No. 11934, DMC Reg. No. 26626



Vihaan (aka B/O Priyanka Verma) 0y 1m 28d / Male REG NO: 3693917 PCS ID: --  
DOB: Feb. 6, 2026 WEIGHT: 3.60 kg HEIGHT: 51.00 cm  
HEART RATE (BPM): 122 SPO2: 76 %  
REF. DOCTOR: Dr. G.K. Singh  
DATE: April 3, 2026, 4:18 p.m.

**PERSONAL HISTORY:**

Term, AGA (B wt= 2.5Kg)

**DIAGNOSIS:**

SS, LC, B/L SVC, DORV, Commitable PM-VSD + additional mid-muscular small VSD (1.8mm) with distal hypoplasia (3.1mm), RPA is adequate (5mm)

**CLINICAL FINDINGS:**

Mild irritability

**INVESTIGATIONS:**

Pulm CTA done @ SGRH on 1-4-2026: Reviewed by me

SS, LC, B/L SVC,

DORV, VSD, Severe PS

LPA ostial stenosis (1.8mm) with distal hypoplasia

RPA is adequate (5mm)

Right kidney is crossed and ectopic

**ECHOCARDIOGRAM:**

Last echo done on previous noted increase in degree of RVH and "concern" for the future LVOT tunnel

**MEDICATIONS:**

TAB CIPLAR 10MG (DISPERSON TABLET IN 10ML WATER & GIVE 4 ML =4MG) TDS

FERIKIND DROPS

VIT D-3 0.5ML

**REMARKS/PLAN:**

Plan: LB and increase oxygenation by LMBTTS

Next visit / follow up

(TO COME FOR FOLLOW-UP AS ADVISED WITH APPOINTMENT OR REPORT ANY ABNORMAL SYMPTOMS)

*[Handwritten signature]*

**S.G.R.H** - Rajinder Nagar, New Delhi - 60, Ph. : 011-42251700,  
42251800, 42254000, Fax No. : 91-11-25861002, EPBX : 011-25750000  
OPD Room No. F-57, Timings : 9.00 am - 5.00 pm Monday to Saturday  
For Appointment Call : +91 9873818788, OPD ☎ 011-42251757,  
Mobile : +91 9811118187, e-mail : [dr.raja\\_joshi@yahoo.com](mailto:dr.raja_joshi@yahoo.com)

For Online Consult, Doctor ID : 53

**myFollowUp**

Available on the App Store | Get it on Google Play



# SIR GANGA RAM HOSPITAL

Trust of Generations



H-2008-0017  
Since June 16, 2008



MC - 2194

## Clinical Laboratory Services Department of Biochemistry

Name : MASTER B/O PRIYANKA , Age/Sex : 8 Wks/Male  
 Registration No. : 3693917 Ward No. :  
 Lab Request No. : 9926085280 Room No. :  
 Episode No. : OP16029016 Location Type: Out Patient  
 Location : CENTRAL INVESTIGATION CENTRE Collected On : 31 MAR 2016 10:18AM  
 Referred By : Dr. Raja Joshi Received On : 31 MAR 2016 11:59AM  
 Ext. Doctor : Reported On : 31 MAR 2016 11:56AM  
 Specimen : Blood Released by : [Signature]  
 Printed on : 31 MAR 2016 02:00PM

Investigation	Results	Units	Bio.Ref.Interval	Test
BUN, SERUM	13.80	mg/dL	(4.00-19.00)	Biochemical (Urease/GLDH)
CREATININE, SERUM	0.34	mg/dL	(0.17-0.14)	Radio Kinetic (IDMS)

-----{END OF REPORT}-----

Note:- (C) after result of a test indicates, it is critical. Needs Attention

1. This is a Computer generated report, No Signature required.
2. Content of this report is only an opinion, not the diagnosis.
3. The report shall not be reproduced, except in full, without permission.

<<< Page: 1 of 1 >>>



## CT REPORT

Patient Name	: B/O PRIYANKA ,	Age/Sex	: 1 Months/M
Reg. No.	: 3693917	Ward No.	:
Episode No.	: OP16034107	Room No.	:
Imaging No.	: 18381253/15	Executed On	: 01-Apr-2026 06:00 (E:10:00)
Location	: CT SCAN	Location Type	: OPD DD
Referred By	: Dr. Raja Joshi	External Doctor	:

CT PULMONARY ANGIOGRAPHY:

Post-contrast helical CT pulmonary angiography was performed using a 128 mm acquisition on Phillips Ingenuity CT after intravenous injection of 100 ml of contrast medium. Scans were obtained in the plain, arterial and venous phases. 3D MIP reconstructions were also obtained.

Clinical Details: Patient is a known case of DORV and LPA stenosis and bilateral SVCs.

CECT THORAX:

Thymus is defined.

Trachea and tracheal bifurcation appear normal. No mediastinal or hilar lymphadenopathy noted. No significant bronchial compression noted. Mediastinal tubular structures are defined.

Lungs are clear and well expanded. No pleural effusion seen.

Screening of the upper abdomen viscera reveal an ectopic right kidney, overlying the aorta.

The vertebrae appear unremarkable with no evidence of an obvious skeletal anomaly.

ANGIOGRAPHIC FINDINGS:

The heart is of normal size with levocardia.

There is a communication between the atrium. There are two communications between the ventricles suggestive of VSDs. The right atrium and right ventricle are dilated.

The aorta arises from the right ventricle. The ascending aorta measures approximately 13.8 mm. The arch is left sided and shows a bovine branching pattern with a combined origin of the right brachiocephalic and the left common carotid arteries, followed by the left subclavian artery. It is normal in caliber. The descending aorta also appears normal.

## CT REPORT

Patient Name	:B/O PRIYANKA ,	Age/Sex	:1Months/M
Reg. No.	:3693917	Ward No.	:
Episode No.	:OP16034107	RoomNo.	:
Imaging No.	:18381253/15	Executed On	:01-Apr-2026 08:48
Location	:CT SCAN	Location Type	:OPD
Referred By	:Dr. Raja Joshi	External Doctor	:

The main pulmonary artery arises from the right ventricle. It is marked and measures approximately 3.9 mm in diameter. It shows normal division into right and left pulmonary arteries. The right pulmonary artery measures approximately 5 mm in diameter. The left pulmonary artery is narrowed to approximately 3.1 mm in the proximal aspect for a length of approximately 7 mm. Thereafter, the main pulmonary artery measures approximately 3.1 mm just before the branching. The segmental and subsegmental branches show normal lobar, segmental and subsegmental branches.

The superior and inferior pulmonary veins bilaterally show normal drainage into the left atrium. Bilateral innominate veins continue as normal. The right sided SVC and the suprahepatic IVC show normal drainage into the right atrium. The left sided SVC drains into the coronary sinus.

**IMPRESSION:** CT findings could be consistent with ASD, VSD, DORV, marked stenosis main pulmonary and left pulmonary arteries and normal SVCs.

Note is made up of ectopic crossed kidney.

**SUGGEST:** Clinical Correlation.

Dr. Anurag Yadav  
Consultant Radiologist

MT-Kamalpreet Kaur



# Sir Ganga Ram Hospital

Rajinder Nagar, New Delhi-110060

## INVOICE

Sir Ganga Ram Pharmacy

(Drug License Nos. : DL-RAJ-115931, DL-RAJ-115932, DL-RAJ-115933, DL-RAJ-115934, DL-RAJ-115935, DL-RAJ-115936)

Bill No: SGRH/PHC/24/26-27  
 Status: Retail  
 Patient Name: B / O PREYANKA  
 Prescribed By: Dr. Raja Jishi (GAA9512) (Sr. Consultant) ( )  
 Printed On: April 01, 2026

Bill Date: 01/04/2026, 02:24:44  
 GST Reg. No.: 07AABTS4368E  
 Patient Reg. No.: B / O PREYANKA  
 Printed By: Vandana

Sr. No.	Item	HSN	Batch	Expiry	MRP	Rail	SLI	GST %	Disc	Value
1	Neoflon Pro ( 24 G ) - Bd	90183930	5274638	2028-09-30	390.00	111.11	3.00	5.00	0.00	1170.00
2	Stopcock 3 way (70876.20 - vygon)	90189099	180424FE	2029-04-18	246.10	111.11	2.00	5.00	0.00	492.50
3	Lectrocath IV extension tubing ( 100 cm ) - Vygon 1155.10	90189099	270325EK	2030-08-31	185.50	111.11	1.00	5.00	0.00	315.00
4	Mucomix 200 mg Injection ( N - Acetylcysteine )	30049099	IACNA1502	2011-11-11	111.11	111.11	24.03	3.00	5.00	75.89
5	TEGADERM 1610 DRESSING - 3M	30051020	R02250991	2011-11-11	188.06	111.11	184.82	2.00	5.00	388.12
6	Microdrip Iv Set ( Pedia Drip Plus ) - Romsons	90189099	11111111	2011-11-11	311.00	111.11	298.19	1.00	5.00	311.00
7	Easyport 500 ml Injection Two Part - Eurohead ( Dextrose 5% + NaCl 0.45% )	30011111	11111111	2011-11-11	309.38	111.11	294.85	1.00	5.00	309.38
<b>Total Amount</b>										3061.19
<b>Less Discount</b>										0.00
<b>Payable Amount (In words)</b>										three thousand sixty one rupees only
<b>Total Payable</b>										3061.00

### GST Summary

GST %	Taxable Amt	CGST Amt	SGST Amt	Total Amount
5.00	2915.43	72.88	111.76	3061.19
<b>Total</b>	<b>2915.43</b>	<b>72.88</b>	<b>145.76</b>	<b>3061.19</b>

### Payment Detail

Type	Machine	Amount
Cash		3061.00

### Note :

- All Prices are inclusive of tax.
- Refunds of medicines only on purchase date on submission of original bill.
- No Refunds will be done on old chain items.
- No refunds without original bill.
- All disputes subject to court.

Prepared By:-

*Vandana*  
Vandana Verma (GAA9545)



# SIR GANGA RAM HOSPITAL

RAJINDER NAGAR, NEW DELHI-110060  
PHONE: 011-42254000 (30 Lines); 011-35125600 (30 Lines); Fax: 25861002  
GSTIN No.: 07AABTS4366E1ZH, HOSPITAL PAN No.: AABTS 4366E

SIR GANGA RAM HOSPITAL  
CT-MRI  
BILL CUM RECEIPT

and click on Patient Portal

visit [www.srg.com](http://www.srg.com)

Reg. No. 13693917  
OPD No. 10P16034107  
Name MASTER D/O PRIYANKA  
Age 28 M  
Address VILL BEHTA POST  
AIRA BEHTA  
LAKHIMPUR KHIRI  
UTTAR PRADESH  
UTTAR PRADESH  
Phone 7607989214  
Location CT SCAN

Bill No. 17022  
Bill Date 30/11/2023  
Sex M  
Internal Re. No. 10111  
Hosp/PSU Re. No. 10111


Exp. 10/11/2023  
GSTIN: 07AABTS4366E1ZH  
GST No: 07AABTS4366E1ZH

No.	Particulars	Unit	Pr.	Amount
1	CT ANGIOGRAPHY THORAX AND DESCENDING/THORACTIC AORTA			19500.00

Total : 19500.00  
Amount Paid : 19500.00

(Received a sum of 19500.00 Rupees only)

Sl. No.	Particulars	Amount
1	CT SCAN	19500.00
Total		19500.00



For Cancellation / Refund of the Bill, any identity Proof in the form of Photo ID, Aadhar Card, Pan Card, Driving License, Passport is mandatory

PEDIATRIC  
paediatric  
25-2026/1  
2/2026 12

# SIR GANGA RAM HOSPITAL

Trust of Generations

07AABTS 4366 E1ZH  
No: 999316

## OPD BILL CUM RECEIPT

Reg. No. : 3693917  
OPD No. : OP16037356  
Name : MASTER VIHAAN  
Age/Sex : 8 W/Male  
Address : VILL BEHTA POST  
AIRA BEHTA  
LAKHIMPUR KHIRI  
UTTAR PRADESH  
UTTAR PRADESH

Consultant : PEDIATRIC CARDIAC SCIENCE  
Department : Pediatric Cardiology  
Bill No. : 25-2026/1-2027/Ca/O/0002572  
Bill Date : 02/04/2026 04:05PM  
Hosp/Unit : SELF

Mode : PRIVATE OPD CLINIC

No.	Particulars	Price	Amount
1	SHORT DURATION SEDATION IN PCS ICU - DOCTOR FEE	3090.00	3090.00

Total : 3090.00  
Amount Paid : 3090.00

(Received with thanks from MASTER VIHAAN, a sum of Rupees Three Thousand Ninety only)

Payment Details

Sr No	Mode	Particulars	Amount
1	Cash		3090.00
Total			3090.00

Signature  
ABhishek

For Cancellation of this bill, any identity Proof in the form of Photo ID / Aadhar Card / PAN Card / Driving License is Mandatory. Kindly process any refund related issue within 15 days only.

Reg No- 3693917



## Department of Pediatric Cardiac Sciences

**Sir Ganga Ram Hospital**

Rajinder Nagar, New Delhi - 110028

Received with thanks a sum of (Twenty-Five Thousand Rupees) (Rs. 25,000/-)

From..... Vihaan aka B/O Priyanka Verma (96701 18414989214).....

In favor of Advanced Booking for Admission 01.04.2026 and Surgery 27.04.2026.

Date: 16.04.2026

Signature

Note:- Non Refundable

F PCS 01/04/2026 : Ashish Katiyar



Department of Pediatric Cardiac Sciences  
Sir Ganga Ram Hospital



**DR. NEERAJ AGGARWAL**

MD, (Peds), FNH, RGUHS (Pediatric Cardiology)  
Senior Consultant Pediatric Cardiologist  
E-mail : drneeraj\_12@yahoo.co.in  
DMC Regn No. : 25394

**DR. MRIDUL AGARWAL**

MD (Peds), FNB (Pediatric Cardiology) National Board  
Senior Consultant Pediatric Cardiologist  
E-mail : drmridul@hotmail.com  
DMC Regn No. : 35769

**DR. JASLEEN KAUR**

MD, (Peds), DrNB (Pediatric Cardiology)  
Associate Consultant Pediatric Cardiologist  
E-mail : dr.jasleen34@gmail.com  
DMC Regn No. : 62646

24/04/2026

D.O.B - 06/02/2026

Vihaan (aka B/o Priyanka Sharma)

2 months / Male

W = 4.3 kg

95% 74%

EF = 121

Do RV, V1, V5  
LPA Acute low ser

Bit SVL

Bovine Ave.



Topic RT  
Kidney

Admission

Admission ↓ PCS

in Cat - III

Echo

Do RV

- normal

- trace with PM enlargement

& LPA stenosis.

LA Ach

- include POA to LPA

29/4/26



# Sir Ganga Ram Hospital

SGRH/Fin Consl/F-215

## Financial Counselling

Specialty PCS Admitting Consultant Dr Raja Joshi

Patient Name	VIHAAN (R/O PRIYANKA VERMA)			
Age	DOB = 6.2.2026			
Sex	male			
Paying Status	TPA	CORPORATE	SELF PAYING	
Registered Mobile No.	9670989213			
Provisional/ Final Diagnosis	DORV, VSD, PS, severe LPA shunt			
Admission Status:	Planned		Em:	
Date of Admission:	26/4/2026			
Surgery (ies) / Treatment (s) Planned	Left med BTTS			
Desired Bed Category	Premium Suite	Suite	Deluxe	Cat 3 DAY CARE #

### FINANCIAL ESTIMATE

### CHARGES

Hospitalization	Approx Days:	2	
Intensive Care, if any	Approx Days:		
Major Investigations			
Operation / Procedure	→ 4 Lo		
OT Charges	Stay / 10 days	25k/day	
PAC + Anesthetist fee			
Surgeon Fee			
Implant (s), if any		1.5-10k/day	
Major Drugs / Consumables, if any			
Other (Consultant visit, Dietician, MRD, Equipment, Blood/Component)			
<b>TOTAL</b>	<b>APPROXIMATE</b>		₹

# DAY CARE ADMISSION PATIENTS DO NOT REQUIRE FURTHER HOSPITALISATION IN PATIENTS INTEREST AS PER DECISION OF CONSULTANT

\*Alternative Medicine, Cancer Therapy, Heart Rehab, Dialysis, Lithotripsy, Minor OT, Ventilator charges are same in all categories

(Shaded area to be filled by Operating Consultant)

The estimate is based on past observation for this Surgery / Procedure / Treatment, Any change in treatment/another specialty or unforeseen circumstances necessitating additional investigation and treatment will increase costs. Upgradation of bed / room will invite higher charges from date of admission. Intensive care charges range from Rs. 50,000-80,000 or even higher per day based on intensity of treatment/ use of special equipment. Packages have INCLUSIONS and EXCLUSIONS. Package rate is limited to a specific period of treatment only, and treatment beyond the specified period will be charged as per actuals. Final Bill may vary based on length of stay / change in / additional treatment given/ use of special drugs / equipment in best interest of the patient.

I HAVE READ /HAVE BEEN EXPLAINED THE ABOVE IN A LANGUAGE THAT I UNDERSTAND AND I ACCEPT TO PAY HOSPITAL BILL RAISED FOR ME/ MY PATIENT

DATE: 24/4/26

SIGNATURES:

[Signature]  
PATIENT/RELATIVE

[Signature]  
CONSULTANT

FINANCIAL COUNSELLOR



SGRH/DM/MC/Cost -Trtmt/F-218

Ms. Rev

# Sir Ganga Ram Hospital : New Delhi

## MEDICAL CERTIFICATE FOR COST OF TREATMENT

Certificate No: DM/MC/FE/ Pediatric Cardiac Sciences / 2026

(Department)

(Running No.)

1	Name	:	Vihaan (aka B/o Priyanka Verma)
2	Age	:	1 month 11 days
3	Sex	:	Male
4	Adhaar No	:	
5	Patient Registration No	:	3693917
6	Date patient examined	:	17/03/2026
7	Brief Clinical Summary (Only relevant salient features like Nature of illness Symptoms Probable cause)	:	Cyanosis (SpO2) 85%
8	Diagnosis	:	Cyanotic CHD: DORV, PM-VSD, mild mitral regurgitation, Severe PDA, severe segmental LPA stenosis.
9	Treatment Planned	:	Duct is still patent, PA flow: PDA, PDA shunt (no duct; on pump)
10	Inpatient / Outpatient	:	Inpatient
11	Duration of hospitalization if any	:	
12	Cost of Treatment	:	₹ 5,00,000/-
13	Purpose for which medical certificate issued	:	for financial assistance
14	Medical Certificate Addressed to	:	G. M. Fund, UP

Patient: Umbilical cord impression

Date: 17/03/2026

Signature of Consultant: [Signature]  
 Dr. (Prof.) RAJA JOSHI  
 MCh (CVS), Fellow (Peds Card Surg. USA)  
 Senior Consultant, Pediatric Cardiac Surgeon  
 Head, Dept. of Pediatric Cardiac Sciences  
 Sir Ganga Ram Hospital  
 MCI Reg. No 11934 DMC Reg No 26626

Date: 17/3/2026

Signature of Director Medical: [Signature]  
 Director Medical  
 Dr. SUCHITA KATOCH  
 Medical Superintendent  
 Sir Ganga Ram Hospital  
 Rajinder Nagar New Delhi-110050

Signature of Notary: [Signature]  
 NOTARY ADVOCATE  
 Date: 17/3/2026  
 Validity upto: 17/5/2026